STEREOROENTGENOGRAPHY

Pulmonary Tuberculosis

BY

KENNON DUNHAM, M. D.

PART I

THE SOUTHWORTH COMPANY

TROY, N. Y.

THE LIBRARY
OF
THE UNIVERSITY
OF CALIFORNIA
LOS ANGELES

GIFT

OF

LOUIS B. ROCKLAND

Stereoroentgenography

PULMONARY TUBERCULOSIS

KENNON DUNHAM, M. D.

PART I.



PUBLISHED BY

THE SOUTHWORTH CO.

TROY, N. Y.

Biomedical
Library
WF
300
D921a
pt. 1

Copyrighted by
THE SOUTHWORTH COMPANY, Publishers
Troy, N. Y.

PULMONARY TUBERCULOSIS

By KENNON DUNHAM, M. D., Cincinnati, Ohio.

Visiting Physician, Cincinnati Tuberculosis Sanatorium, Chief in Clinic in Tuberculosis Medical Department, University of Cincinnati.

THE diagnosis of tuberculosis is not new. It was old before Hippocrates wrote. But it is still difficult, and the physician who does not know this, has failed to check up his work, or has learned most of his knowledge from books.

¶ It was my intention to present to you the points which I considered of value in making an early diagnosis of tuberculosis, but that left so little time for the presentation of my own work and looked so much like a compend used by the lazy student that I have changed my mind.

¶ I trust that you will understand that I consider a carefully taken history and a thorough physical examination of the utmost value.

¶ Further—that I know that the X-ray has its limitations.

¶ What I bring to you is my own creative work towards the diagnosis of tuberculosis.

¶ My claims of priority for this work are not based, as some have supposed, upon the origin of the stereoscope or the stereoroentgenogram.

¶ What I have done is to adopt, not create, a practical technique. I have proven the cause of the tree-like shadows seen upon a normal chest plate to be due to blood vessels, bronchi and connective tissue and not due to either alone. And further, that the connective tissue is the more important.

707339

Digitized by the Internet Archive
in 2007 with funding from
Microsoft Corporation

http://www.archive.org/details/stereoroentgenog01dunhiala

¶ I have described the normal chest plate, and shown that characteristic variations occur in tuberculosis. This reading has been verified by over two thousand carefully examined cases, worked up in conjunction with able men in the Cincinnati Tuberculosis Sanatorium and Johns Hopkins Hospital. Also more than two hundred autopsies have been made of these cases.

¶ Lastly, I point out that these tuberculous markings are due to tubercles scattered along a branch or a twig of the bronchial tree. This accounts for the constant findings in tuberculosis on the roentgen plate, of a triangular area of increased density covering the linear markings of one or more trunks. This density has its base to the pleura and its apex towards the hilus and is connected with the hilus by a heavy trunk. The character of this density varies according to the age and extent of the lesion and is caused not by a few tubercles, but by myriads of tubercles scattered along the bronchial tree.

¶ When Avenbruger, in 1761, introduced immediate percussion, followed by Piorry's gift of the pleximeter, and Laennec, in 1819, gave us the stethoscope, they added the scientific element to the study of the thorax, which had previously consisted simply of a review of the history and observation of the clinical symptoms. The usefulness of these instruments was rapidly increased by the work of a host of men of who Skoda and Flint are prominent examples. This development consisted not only in greater refinement in the use of these instruments, but in the study of the relation of adventitious sounds to pathological conditions. Thus, in the latter half of the nineteenth century, these methods were brought to a high degree of accuracy and

were generally used by the profession. Nevertheless the objective findings of a physical examination at times become very subjective, since men are at the mercy, not only of their lack of knowledge, but of their personal physical conditions. It is very easy to be misled as to the importance and significance of certain findings, by the complaints and symptoms of the patient, as well as by unusual distortions of the viscera,[1] such as the simulation of a cavity by the dragging of the trachea into the right thorax[2] or the signs of hyperresonance when an entire lobe has been replaced by fibrous tissue and multiple cavity formation.[3]

¶ Similarly the physical examination of a chest requires acute perception and keen concentration, which must vary greatly, not only in different men but in the same man at different times. And even if these observations could be standardized, their interpretation and correlation, upon which the diagnosis depends, must still be subjective. Thus we see that the pleximeter and stethoscope are not instruments of precision, and that an instrument of precision is the greatest need in this work, if we are to replace individual and varying judgments with scientific accuracy.

¶ It was to fill this need that I employed the X-ray, and brought to perfection the stereoroentgenograms of the chest, which are records, rather than observations. The use of the X-ray with the fluoroscope, which presents an evanescent image, is of great value in the study of moving parts, but, like all previous work along this line, gives us nothing tangible for renewed study or comparison. It is an observation, not a record. It is these records, the stereoroentgenograms, that enable us to check up the evidence of the history, clinical symptom, signs, palpation, percussion and auscultations.

1 Stereos 18, 19, 20, 21, 22, 23, 24, 25, 26. 2 Stereo 22. 3 Stereo 24.

¶ Stereoroentgenological examination of the chest is the study of the thorax by means of a pair of X-ray plates, so taken that, when seen through a stereoscope, they present a single image of the different densities of the chest in perspective. A roentgenogram or X-ray plate is a photographic plate upon which an image has been produced by the action of roentgen-rays, after penetrating the subject, thus recording its difference of density.

¶ Roentgen-rays are produced by a highly specialized electrical apparatus, and differ from light rays in that they are invisible and penetrate matter practically inversely in proportion to its density. They thus produce a roentgenogram which is not a shadowgraph nor photograph. This, however, corresponds to a photographic negative in that it is developed and fixed in a similar manner.

¶ A stereoroentgenogram consists of two roentgenograms, which have been exposed exactly alike, except that the tube after the first exposure, is moved parallel to the plate six c.m. (the pupillary distance) and then a second exposure is made. These exposures are usually made upon two separate plates; if so, plate one must accurately replace plate two. The patient is exposed in the upright position. My method of exposure is to pass the principal ray of the first exposure through the sixth dorsal vertebrae and of the second exposure through the spine, six centimeters lower. It is needless to state that the object exposed must not move from the beginning of the first to the end of the second exposure.

¶ To see such exposures in perspective most of us must view them by means of a stereoscope. This is an instrument which allows us to replace the target of the tube in its first position with one eye, and its second position with the

other eye, but does not permit either eye to see but its own exposure. Thus is obtained one image, which is seen in perspective.

¶ There are three forms of stereoscope that are generally used in this work. The Whetstone or mirror stereoscope consists of two mirrors set at an angle of ninety degrees, so placed that each mirror presents the reflection of one plate to one eye, thus presenting to the sight a single image in perspective. The only objection to this method is the refraction of the mirrors.

¶ The second stereoscope is the prism stereoscope, which consists of two prisms so arranged as to bring each image to its respective eye. The difficulty here is that of adjustment, both as to pupillary distance, the needed degree of refraction and the proper distance of the plate for observation.

¶ The third is the hand or magnifying prism stereoscope, first described by Brewster, which only views reductions of the original plates, such as we present in the Stereo-Clinic. This stereoscope is easy of adjustment, and convenient in comparing a number of cases, but the proper reduction is difficult and expensive, and even in accurate work much detail is lost. For that reason we cannot show the earliest lesions of tuberculosis in this series.

¶ These technical explanations make clear that three factors are essential to the use of stereoroentgenograms; perfected apparatus, mathematical precision of technique and binocular vision. But, given these, the doctor's work is just begun. In other words, the roentgenographer now presents the plates to the roentgenologist, who is to read or interpret this record. It is here that the value of the stereoscopic-roentgenogram is most evident. The transla-

tion of the roentgenogram into a correct mind-picture of the condition within the chest can only be accomplished by placing the different densities upon their proper planes. Obviously accuracy must be sacrificed when we have the superimposed densities of six to eight inches of vital tissue imaged upon a single plane.

¶ The reading of a stereoroentgenogram consists of an objective description and subjective deductions. My description is outlined here as I use it. I note—

¶ 1. The plates, or the work of the roentgenographer.

¶ 2. The bones, particularly the position of the spine, the corresponding width of the interspaces and the angles of the ribs to the spines; also bone lesions, such as syphilis, etc.[4]

¶ 3. The muscles, height and dome of diaphragm and the position of heart and aortic arch, the pectoral muscle, if seen, or the breasts of the female.[5]

¶ 4. The trachea, its position in the mediastinum and the dorsal vertebra, in front of which the bronchus divides. Also where the bronchi enter the hilus shadow, and especially how the left bronchus shadow passes under the arch of the aorta.[6]

¶ 5. The hilus shadow, how the right and left differ from each other and from the normal, as to size, density, etc. Also the trunks which pass from the hilus towards the periphery.[7]

¶ 6. Right thorax, with its upper, middle and lower divisions and their trunks.[9]

¶ 7. Left thorax, its two divisions and their trunks.[9]

¶ 8. Any abnormalities, or other findings, which would influence my deductions.

4 Stereo 33. 5 Stereo 6, 36. 6 Stereo 11, 32, 7, 34. 7 Stereo 9. 9 Stereos 1, 2, 3, 4, 26, 12, 28.

¶ Let us now examine a normal plate by this outline.

¶ A normal chest plate[10] shows the ribs bounding the lungs on all sides, except below, where we have the diaphragm. The picture is divided into the right and left half by the spinal column and mediastinal tissues, the heart and aorta being quite prominent. Following the spinal column from above down we have the trachea.

¶ As I have my patients turn their heads to the left, the larynx can be made out to the left of the cervical spine; the trachea then passes down the median line and gradually crosses to the right side of the spinal density. Bifurcation occurs normally in front of the body of the fifth dorsal vertebra. The left bronchus should reach the hilus shadow nearly in front of the seventh rib and the right bronchus nearly in front of the sixth interspace. By close study of favorable plates these bronchi can be followed into the right and left hilus. The right can be followed the more often, since the left dips under the aorta, which obscures it for a short distance. The trachea and bronchi are noted as areas of lesser density, bordered by lines of greater density.

¶ The hilus shadow is an irregular area of greater density extending from the heavy central shadow into the lung fields, from a little above to considerably below the sixth dorsal vertebra. So far as I have been able to learn no norm can be described for the hilus. The most ruddy adults may have numerous calcified areas within the hilus and the acute, active cases of tuberculosis frequently have none. But it is a constant observation, that the older the patient the larger and more dense the hilus shadow.

¶ The bronchi pass into the hilus, and the heavy trunks go from the hilus to the lung fields. These trunks have

10 Stereos 6, 36.

anterior and posterior branches, which terminate in fine radiating lines, which are comparatively straight and go in all directions towards the periphery. These latter I have termed linear markings.

¶ Thus, there are the hilus, heavy trunks and linear markings, all of which are of greater density than the parenchyma of the lung.

¶ The trunks may be quite heavy and even studded without indicating disease. Very heavy trunks and hilus shadows, and more especially the calcified areas, are probably, to a large extent, the result of tuberculosis. They have, in my opinion, about the significance of a von Pirquet reaction, viz: infection but not necessarily disease.

¶ The heavy trunks are quite constant in their distribution. By following them it is possible to divide the lung fields into divisions—three on the right, two on the left, which correspond roughly to the lobes of the lungs.

¶ In the upper division, on both sides, there are three groups of trunks, the first passing from the upper part of the hilus, parallel to the spine, toward the apex. The radiations of this first group are seen behind the circle of the first rib, and I call it the vertebral trunks. A second, passing laterally from near the upper part of the hilus, is seen behind the first interspace, which gives it its name. Its linear markings are seen behind the first interspace and the first and second rib. The third group passes laterally from a lower point on the hilus, and is seen behind the second interspace, and has branches extending both anteriorly and posteriorly. It is called the second interspace trunks and its linear markings spread like an infarct behind the second rib, second interspace and third interspace.

¶ As to the middle division on the right, it has but one trunk and it, like the one passing to the lingual tip of the upper left lobe, is not easily made out, except in diseased or in injected specimens. The middle lobe is usually defined by exclusion, but its trunk when seen comes from the hilus well down at an unexpected distance below the upper lobe bronchi, and it is easily mistaken for the numerous trunks of the lower division. The trunk is short and soon divides into an anterior and posterior division, which lies nearly horizontal in the chest, crossing many ribs and interspaces.

¶ The right and left lower divisions are similar, except that on the left, the trunks are partly obscured by the heart and are usually indistinct, due to heart pulsations. They consist of a mass of heavy trunks, more or less matted together, which extend downward from the hilus and pass toward the periphery of the lower lobes.

¶ These I have not classified further except to call especial attention to the trunk which supplied the apex of each lower lobe. The trunk comes from the hilus shadow just below the second interspace trunks of the upper lobe. Anatomically the bronchus which corresponds to this trunk leaves the main stem bronchus much lower than it appears to upon the roentgen plates. On the right side this bronchus lies near and posterior to the bronchus going to the middle lobe and in a similar position on the left side.

¶ The reason that this trunk seems higher on the roentgen plates than in the dissected lung, is because the trunk to the apex is passing up and back, the trunk to the middle lobe is passing down and forward. The hilus density obscures their origin at the main stem bronchus and the trunks are not recognized until they leave the hilus shadow some distance from their origin.

¶ Thus the trunk going to the apices of the right and left lower lobes is seen upon the stereoroentgenogram passing directly toward the observer from the hilus shadow just below the origin of the second interspace trunks.

¶ When the above points have been described we find that normally the spine should be straight, the ribs regular, the corresponding interspaces of equal width, the bones free from lesions.

¶ The right diaghragm should be higher than the left, with both domes well rounded and smooth, each reaching the ribs in the axillary line at a sharp angle. The heart and aorta vary within wide limits.

¶ Normal variations are difficult to describe, because the norm varies with age.

¶ Besides, I have included with the normal many changes which are probably the result of infection, but which have no clinical significance at the time of examination. As is to be expected the hilus, trunks and linear markings become heavier with age just as does the connective tissue.

¶ Necessarily any study of the chest must deal largely with tuberculosis. Differential diagnosis of pulmonary lesions is comparatively simple after we have eliminated the normal and tuberculous chests.

¶ Normal plates, taken with the present technique, do not show the linear markings extending to the periphery. These lines are seen to radiate more or less distinctly from the trunks. In describing the character of these linear markings we have used the terms, "reach the periphery," "radiating," "interwoven," "with large or small mesh," "of increased density," "broadened," "studded," contracted," "obscured by a filmy cloud," and "blotted out," which carry their own meaning.

¶ This is the language of definition to be used, and in it I shall describe the difference between the normal and the tuberculous chest. Bearing in mind, then, these terms and the normal X-ray chest plate, let us consider the stereoroentgenograph of chests in which early but definite signs of pulmonary tuberculosis are found on physical examination.[11] In such cases changes are noted in the hilus shadows, the heavy trunks and especially in the linear markings.

¶ The hilus shadow shows usually an irregular increase in area and density, with here and there small irregular shadows of very marked density.[12] These bright areas of great density are due to the presence in the chest of calcified caseous or fibrous glands, while the increased area of density of the hilus shadow is due to general increase in the fibrous tissue, which accompanies a local or general mediastinitis. Such changes alone are of very slight diagnostic value as regards the presence of active tuberculosis, because a long healed tuberculous lesion or other infection may produce the mediastinal changes. The calcified glands, although usually of tuberculous origin, indicate an old process more or less healed. In fact, the presence of calcified glands, other conditions being the same, would suggest a favorable prognosis.

¶ The second point for consideration is the heavy trunks which, when extending to an involved area, are denser and broader than normal, but similar changes may occur in other diseases, and they alone do not justify a diagnosis of tuberculosis.

¶ The roentgen findings which I have described as characteristic of pulmonary tuberculosis consist of numerous

11 Stereos 9, 10, 11, 12, 13, 14, etc. 12 Stereo 8.

abnormal changes limited to the linear markings of the various trunks. These abnormal densities reach the periphery and are more or less fan-shaped with the apex or the angle of the fan toward the hilus. These densities are not homogeneous, but each triangle has a distinct characteristic marking due to lesions of different densities. The older lesion has the greater density. A plate having a homogeneous distribution of its markings is probably not tuberculous. Each fan-shaped density is connected with the hilus by a heavy trunk.

¶ The character of density causing these triangular changes limited to the linear markings vary greatly in character. At times the linear markings only appear broader, denser, less regular in outline, reach the periphery and are slightly interwoven. At other times their course is studded, sometimes to the obliteration of the lines. As the lesion progresses the alterations become more marked, the linear markings are more broken up, the interweaving closer, the fans contracted, the studdings become larger and denser, even flocculent in character, until eventually all the markings are blotted out and the whole area may appear as a unified mass of increased density.

¶ An active lesion causes the triangular area to appear as a filmy cloud which more or less completely obscures the linear markings.

¶ On the other hand if the linear markings are sharply defined and dense and show clean-cut studdings beyond the trunks a healed lesion is suggested. Often such a triangle is smaller than normal and appears to be contracted.

¶ Tuberculous lesions involving the lung parenchyma with few exceptions show plate changes which extend from

the hilus to periphery, and unless an entire lobe is destroyed the degree of the changes should vary, as I have just stated. This fact is best noted in the upper lobes where the linear markings of either trunk alone may be involved or all may be involved to varying degrees; but if all are slightly but equally involved some etiology other than tuberculosis should be suspected.

¶ Thus one of the most striking characteristics of the tuberculous picture is the variations of density change beyond the different group trunks, in contrast to the general homogeneous change of other diseases which might simulate tuberculosis.

¶ Of course we have border-line cases which must be classified as "Possibly Tuberculous" in which some case of the characteristic alterations are seen, but the puncture is not complete. Changes are seen in the hilus and heavy trunks with suggestive alterations in the linear markings. These cases require careful study and the history, symptoms and physical examinations are essential.

¶ The moderately advanced and advanced cases of pulmonary tuberculosis are readily recognized. In the less advanced cases, careful study will disclose the alterations in the linear markings, heavy trunks and hilus shadow previously described.

¶ If, in such cases the fine linear markings of certain trunks are fuzzy, or seem to merge to form a cloud effect, such as a film of tobacco smoke, active tuberculosis would be suggested.[13]

¶ On the other hand, if the linear markings in a limited area are sharply defined, and dense, and show clear-cut studdings beyond the trunks, a healed lesion is suggested.[14]

13 Stereo 10. 14 Stereos 21, 33.

This condition is emphasized if it is accompanied with heavy, coarse interweavings, which reach to or near the periphery. The heavy trunk, leading to such an area is unusually broad and dense, as is the hilus on the same side. Numerous calcified areas would complete the picture, but such a diagnosis should not be made from the plates alone.

¶ Much has been written as to the importance of calcification of the cartilage of the first rib, both as a diagnostic sign of, and an etiological factor in, tuberculosis. My subsequent study can only confirm my former position—that the calcification of the rib cartilages, especially the first, is more common in males than in females, that it increases in frequency with advancing years, and finally; that its incidence in pulmonary tuberculosis is only accidental, or late secondary change, and that its occurrence is of no diagnostic significance whatever in the individual case.

¶ We have not disproved the assertion that it can be an etiological factor in a small percentage of cases, but my studies lead me to doubt the claim.

¶ What is the pathological change in lung density which causes these markings to differ from the normal markings?

¶ These changes are primarily due to tubercules which are scattered along the bronchial tree to the periphery, that is, to the pleura. It is not one tubercle nor even several conglomerate tubercles which cause these density changes, but it is myriads of tubercles. This was ascertained while working with Dr. W. S. Miller at the University of Wisconsin. And further we learned that very early these tubercles break down and drain into the bronchus. It is my opinion that only when they break down the clinician gets his clicks or rales at the end of inspiration, while the

roentgenogram shows a change in density before this. To understand this you must remember that the change in density is produced by numbers of tubercles which involve an area and not by a few tubercles. It is like one tubercle bacillus which must be seen by a powerful lens, while a growth upon culture media is readily seen by the unaided eye. The work with Miller was prosecuted by studying serial sections taken from lungs which had been X-rayed after removal from the body, so that we were able to section any part of many lungs which showed the characteristic markings. Later when going through the literature I found these statements fully substantiated by Nichol (Beitrage fur Klinische Tuberculose 1914). Thus the pathological changes in lung density which cause these markings are tubercles scattered throughout one or more branches of the bronchial tree.

¶ The normal lung markings are caused by bronchus, pulmonary artery, lymphatics and partly by the pulmonary vein. It is a composite picture and the trunks with their linear markings correspond in location to the bronchial tree. Birch-Hirschfeld's model of the bronchial tree shows this perfectly. This was proven in the laboratory of the Phipps' Dispensary at Johns Hopkins.

¶ One other change, which is almost constant in pulmonary tuberculosis, but which seldom is diagnosed either clinically or radiographically, is pleurisy.[15] Marked localized thickenings and interlobar pleurisy are easily diagnosed,[16] but a diffuse pleurisy, which spreads uniformly over one or both pleural surfaces, usually defies detection. On the other hand, pleurisy, with even a slight effusion, is readily detected and presents a most interesting appearance in the stereoroentgenogram.[17]

15 Stereo 42. 16 Stereos 15, 37. 17 Stereos 13, 14, 41.

¶ The more advanced lesions, such as cavity, pleurisy with effusion, pneumothorax,[18] and distortion of viscera, due to fibrosis, etc., require careful consideration especially as surgical interference can often be of benefit, and because they have great bearing upon the prognosis. A description of these conditions is superfluous, as they are best described in the accompanying stereoscopic reductions. There are many varieties of tuberculosis too, which also are best described in these reproductions.

¶ We have now considered the appearance of the stereoroentgenograms of the normal chest and of the typically tuberculous chest. However, all cases do not fall into these two classes. Clinically, my cases are divided into four groups.

¶ First—Normal, which are non-tuberculous.[19]

¶ Second—Tuberculous.[20]

¶ Third—Possibly tuberculosis, doubtful cases.[21]

¶ Fourth—Diseases differentiated from tuberculosis.[22]

¶ Plates one to five—Experimental work.

¶ It must be clearly understood that the stereoroentgenographic examination does not draw a sharp line of differentiation between these various groups any more than does the clinical examination. In deciding the border line cases, the personal attitude and experience of the examiner is of great importance. We cannot, therefore, set forth any absolute rules to be applied in the classification of every case, but an added brief description of the shadow pictures, which we consider typical of the latter two groups, may be of some assistance.

¶ In the possibly tuberculous cases some of the characteristic alterations are seen, but the picture is not complete.

18 Stereos 27, 28, 29. 30, 31. 19 Stereos 6, 36. 20 Stereos 8, 31, 33. 21 Stereo 32. 22 Stereos 34, 42.

There may be changes in the shadows cast by the hilus and heavy trunks and suggestive alterations in the linear markings, or some other typical alteration. These are the cases that require the most careful study and judgment in reaching a diagnosis. The history, symptoms, and physical examinations are essential in these cases.

¶ There are many non-tuberculous pulmonary lesions, but we will not at this time discuss the stereoroentgenographic appearance of acute pneumonia, gangrene, cyst, etc., except to say that they should not be difficult to differentiate from tuberculosis. There is, however, a large class of cases clinically and radiographically suggesting pulmonary tuberculosis, which, upon examination, disclose interesting and puzzling appearance.[23] The hilus shadow and heavy trunks are increased in area and density, the linear markings are sharply defined, radiate, and often reach close to the periphery. These changes are usually diffuse rather than localized, and there is also an absence of the interweaving and studding characteristic of the tuberculosis cases. I include in this volume pictures of chronic bronchitis and emphysema,[24] metastatic carcinoma,[25] fungus infection,[26] and abscess of the lung,[27] to show their differentiation from tuberculosis.

¶ I have gone into the details of these tuberculous and non-tuberculous chest pictures so as to make it possible not only for an X-ray man, but for every physician interested in chest examinations to understand these reproductions. I do not mean that any one without painstaking practice, could, given a stereoroentgenogram, either get the objective findings or make the subjective deductions necessary

23 Stereos 33, 34, 35, 37, 38, 39, 40, 42. 24 Stereo 34. 25 Stereo 39. 26 Stereos 40, 41, 42. 27 Stereo 38.

for the most elementary diagnosis; but I do mean that any one may now know what can be done, and so may not shirk the responsibility of a sure and early diagnosis of that dread disease against which forewarning is the only effective arming.

¶ To men who have never known the illumination of having their previously uncontested physical examinations constantly checked up by the bold black and white of stereoroentgenograms, the claim I make for the necessity of their use seems based upon an ability to make good physical examinations or an undue enthusiasm for the Roentgen ray. But constant use of the roentgenological method since 1909, both in conjunction with my own physical examinations and those of some of the ablest men in the world, as well as with post-mortems, has enabled me to state authoritatively that stereoroentgenological examination of the chest has added that scientific element to the study of tuberculosis which marks another decided advance toward the understanding and the elimination of the disease.

List of Cases.

CLASS I.—Non-Tuberculous.
CLASS II.—Tuberculous.
CLASS III.—Possibly Tuberculous.
CLASS IV.—Diseases differentiated from Tuberculosis.
CLASS V.—Experimental.

Class V
- Stereo 1—Cadaver—Bismuth injected through trachea.
- Stereo 2—Injected lung of Stereo 1, removed from body.
- Stereo 3—Heart and lungs removed.
- Stereo 4—Heart removed, lung inflated.

Class II
- Stereo 5--Tuberculosis, lung removed.

Class I
- Stereo 6—Normal chest, with fractured clavicle.
- Stereo 7—Marked Scoliosis.

Class II
- Stereo 8—Tuberculous Mediastinitis.
- Stereo 9—Early Tuberculosis.
- Stereo 10—Active Pulmonary Tuberculosis.
- Stereo 11—Early Tuberculosis.
- Stereo 12—Unilateral Tuberculosis.
- Stereo 13—Active Pulmonary Tuberculosis, effusion at left base.
- Stereo 14—Pulmonary Tuberculosis, with effusion.
- Stereo 15—Pulmonary Tuberculosis, Interlobular Pleurisy on right.
- Stereo 16—Pulmonary Tuberculosis, with Emphysema and thickened pleura.

Class II

Stereo 17—Pulmonary Tuberculosis with abscess.
Stereo 18—Fibroid Tuberculosis.
Stereo 19—Fibroid Tuberculosis, with lesion.
Stereo 20—Fibroid Tuberculosis and distortion mediastinal viscera.
Stereo 21—Fibroid Tuberculosis, with distortion of viscera.
Stereo 22—Fibroid Tuberculosis, with distortion of viscera.
Stereo 23—Fibroid Tuberculosis, cavities at apices
Stereo 24—Fibroid Tuberculosis, with cavities.
Stereo 25—Fibroid Tuberculosis, with cavity formation.
Stereo 26—Fibroid Tuberculosis, with cavities.
Stereo 27—Pulmonary Tuberculosis, with Hydro-Pneumothorax.
Stereo 28—Lung before therapeutic pneumothorax treatment.
Stereo 29—Lung partially collapsed.
Stereo 30—Lung completely collapsed.
Stereo 31—Lung expanded after artificial pneumothorax.
Stereo 32—Bilateral seventh cervical rib.
Stereo 33—Healed Tuberculosis and Syphilis.

Class IV

Stereo 34—Chronic Bronchitis, with Emphysema.
Stereo 35—Arterio-sclerosis, with Emphysema.
Stereo 36—Syphilis, with appearance of normal chest.
Stereo 37—Right sided Interlobular Pleurisy.
Stereo 38—Abscess of the lung.

Class IV
- Stereo 39—Secondary Carcinoma. Hydro-pneumothorax on right.
- Stereo 40—Lung Fungus—A.
- Stereo 41—Lung Fungus—B.
- Stereo 42—Lung Fungus—C.

Class V.—Experimental.

Cadaver—Bismuth Injected Through Trachea.
[Stereo 1.]

¶ A rubber tube containing shot was passed through the descending vena cava into the heart. The right upper lobe is only partially filled and shows the trunks. The upper lobe bronchus leaves the right bronchus high up between the fifth rib and first interspace. The vertebral trunk is given off from this branch, passes upward to the clavicle parallel to the spine. The branches from this trunk which we term linear markings, are not shown in this illustration, but radiate from the ends of this trunk and are seen upon plates of living subjects, behind the circle of the first rib. Given off from this upper right bronchus nearer to the

Stereo 1. **Serial N°. 1194**

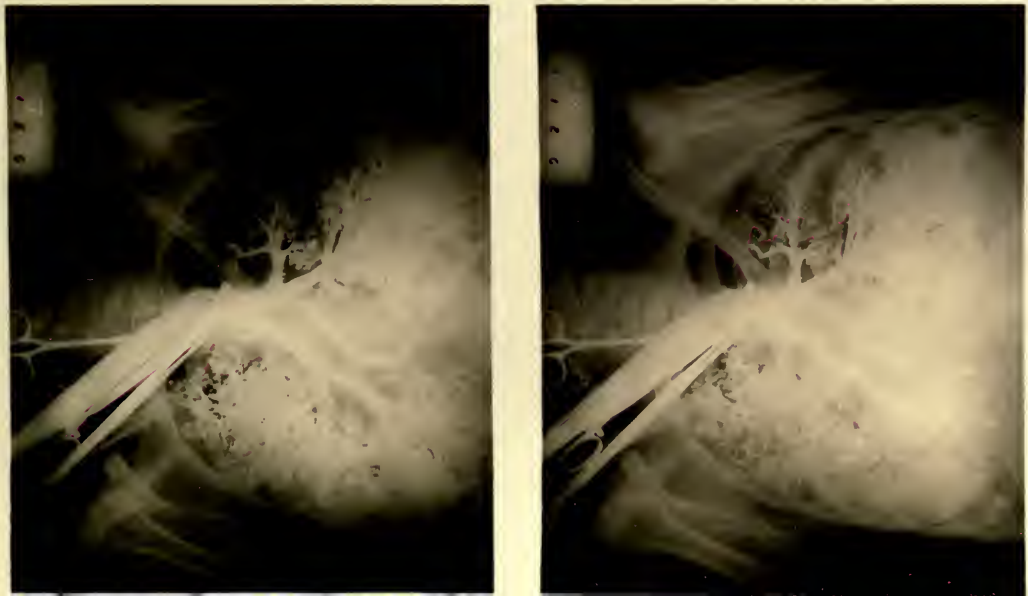

bifurcation, is seen another branch which quickly divides the posterior branch coming toward the fourth rib, the anterior branch going horizontally towards the lateral wall. The markings which radiate from this posterior branch are seen behind the first interspace, and those which radiate from the anterior branch are seen behind the second interspace. Another trunk given off from the upper lobe bronchus lies more anteriorly and also has two branches, an upper, which is posterior, and a lower, which is anterior. The markings radiating from the upper branch are seen behind the first interspace, and the markings which radiate from the lower branch lie behind the second interspace.

¶ Thus the vertebral trunk which I described in reading the plate has a true anatomical basis, but the first and second interspace trunks are not anatomical divisions; that is, the densities described as the first interspace trunk is produced by the upper or posterior branches of two medium sized bronchi which are seen to lie behind the first interspace; whereas, the densities which I have called the second interspace trunks consist of the lower or anterior branches of these same medium sized bronchi, and are seen upon our X-ray plates behind the second interspace. The lower branch of the upper lobe brohchus, which is seen very clearly on this plate and which passes downward and forward, has an upper branch, which is also described with the second interspace trunks, and a lower branch, which is not usually made out during life.

¶ Below the upper lobe bronchus no divisions are given off for quite a distance, and then are seen three branches coming off from different points on the circumference of the main bronchus near a common plane. The posterior

and most lateral of these pass to the lower or posterior lobe, while the anterior goes to the middle right lobe and divides into two medium sized bronchi, which are only made out during life when disease of the right base is largely limited to this lobe.

¶ In life the main bronchus and the trunks near the main bronchus just described are largely obscured by the heavy densities called the hilus shadow. The diversions of the lower right lobe in these plates are obscured by an excess of bismuth.

¶ The tube containing shot has been passed into the heart through the descending vena cava. It is somewhat distorted, but shows roughly how the blood passes from the right auricle to the right ventrical with relation to the X-ray plate.

¶ In striking contrast to the right upper lobe bronchus, the left upper lobe bronchus is given off from the left bronchus much lower, between the fifth interspace and second interspace. This is anatomically necessary because the aorta passes over the left bronchus. Nevertheless, for practical purposes, the vertebral, first interspace and second interspace trunks are seen and described the same in the upper left as in the upper right. The only difference being that the long anterior or lingual tip of the upper left lobe does not exist on the right side, and on the left is seldom detected during life. In this injected specimen it is clearly made out. The individual branches of the lower left, as of the lower right, are difficult to classify.

Injected Lung of Stereo 1 Removed from Body.
[Stereo 2.]

¶ The tube containing shot passing through the descending vena cava has been brought out of the heart, and the aorta can be seen passing over the left bronchus. There has been an unsuccessful effort made to inject one of the arteries of the upper right and one of the veins of the upper left.

¶ This stereo has been produced to show the upper, middle and lower divisions on the right, with their respective trunks, and the upper and lower divisions of the left side, and to again call attention to where the bronchi are given off, because this is most important when trying to make out the location of the various lobes on these stereoscopic plates.

Stereo 2. **Serial N° 1189**

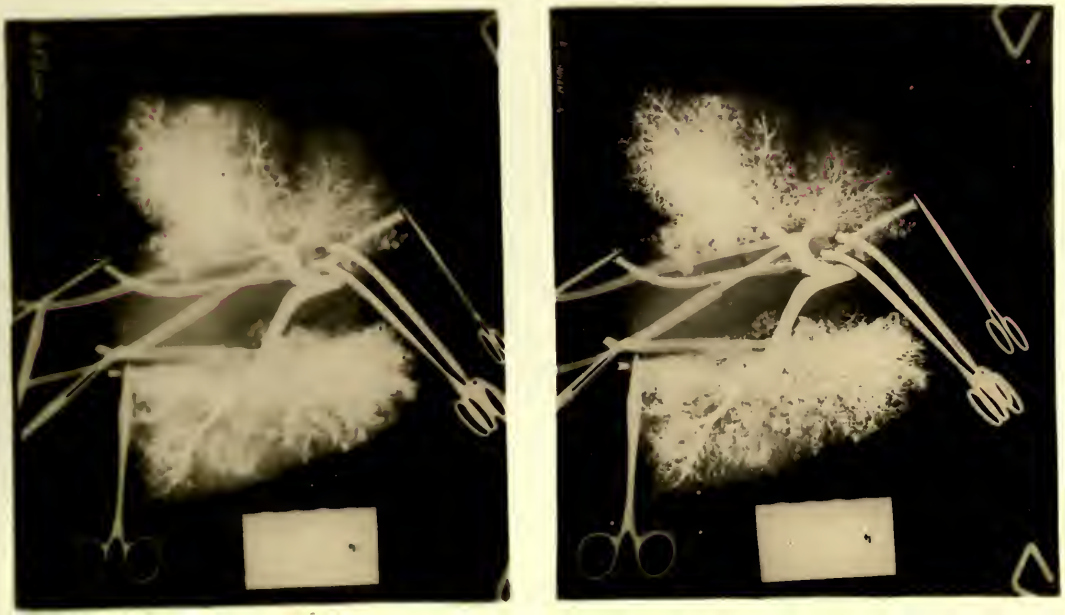

Heart and Lungs Removed.
[Stereo 3.]

¶ The right lung is partially inflated. The left lung shows how little could be seen if the lung were not an air containing organ. Note the aorta passing over the left bronchus and the large calcified nodes. The one in the bronchial angle was found to be caseous with a great number of calcified flakes, especially around the periphery, whereas, those two nearest it, around the bronchus of the right lower lobe, were found to be solid calcified bodies. The mulberry appearance of the former is characteristic of these partially calcified caseous glands, and I have termed them on the plates caseo-calcareous areas of increased density. Further, the three lobes on the right side can be made out.

Stereo 3. **Serial N° 1173**

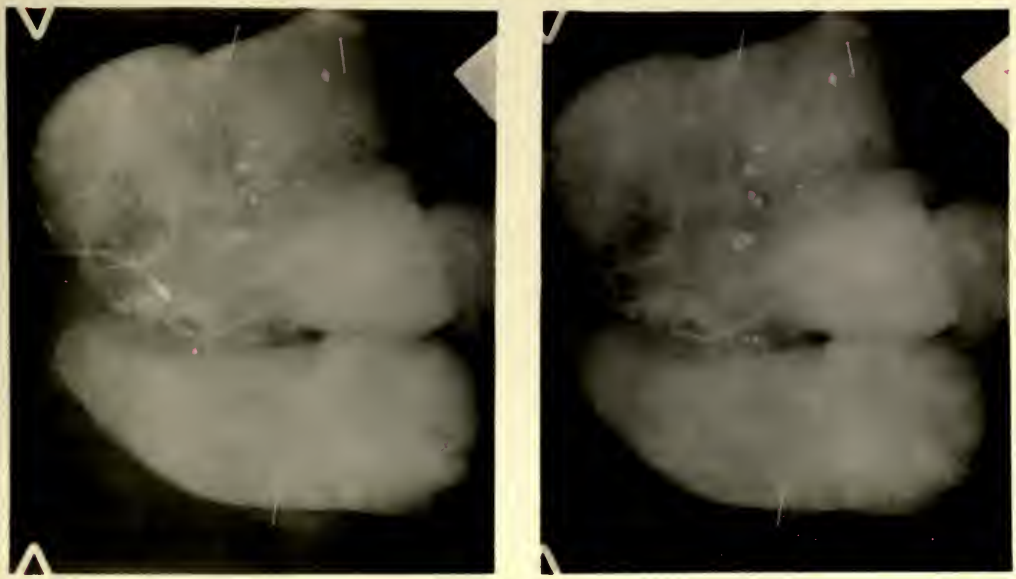

Heart Removed, Lung Inflated.

[Stereo 4.]

¶ Aorta passes over left bronchus; caseo-calcareous gland, mulberry type, in bronchial angle.

¶ Illustration shows relation between lobes of lung and so-called divisions, three on right and two on left, described in fore-word of this volume.

¶ Right bronchus passes straight from inflating tube. Careful study reveals the vertebral, first interspace and second interspace trunks of upper right. A large trunk is given off right bronchus farther down, which passes directly towards a calcified node, in the lower part of middle lobe. This is middle lobe bronchus.

¶ Lower lobe bronchi are given off below, or posterior to, middle lobe bronchus.

¶ Left bronchus passes from inflating tube in a curve, dips under the aortic arch and soon divides into upper and lower lobe bronchi. Upper and lower divisions easily seen. Three trunks of upper division not seen.

Stereo 4. **Serial No 1194**

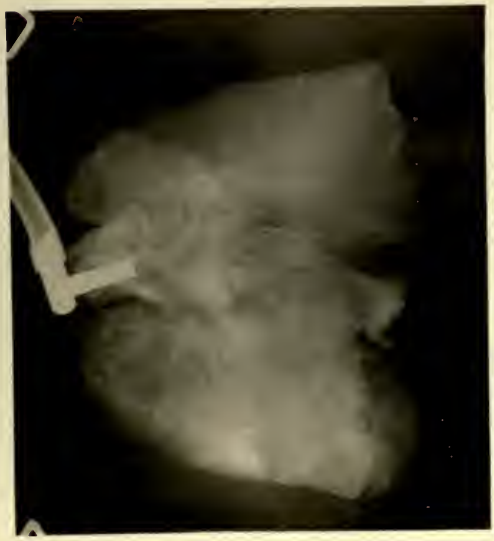

THE LIBRARY
OF
THE UNIVERSITY
OF CALIFORNIA
LOS ANGELES

GIFT

OF

LOUIS B. ROCKLAND

Class II.—Tuberculous.

Tuberculous. Lung Removed.

[Stereo 5.]

¶ Here is shown an inflated lung removed from the body. Extensive cavities are seen in the upper left lobe. The aorta passes over left bronchus. The right side as inflated shows the extensive calcified areas, one caseo-calcareous gland, the bronchus going to lower right lobe, and typical advanced tuberculous studdings which obscure the trunks and linear markings. These extend from the hilus to the periphery and are not uniformly involved throughout any area except where total destruction has taken place.

¶ The many chambers of the cavities in the upper left can be clearly made out and they invade the entire upper lobe with the exception of the long anterior tip.

Stereo 5. **Serial No. 1174**

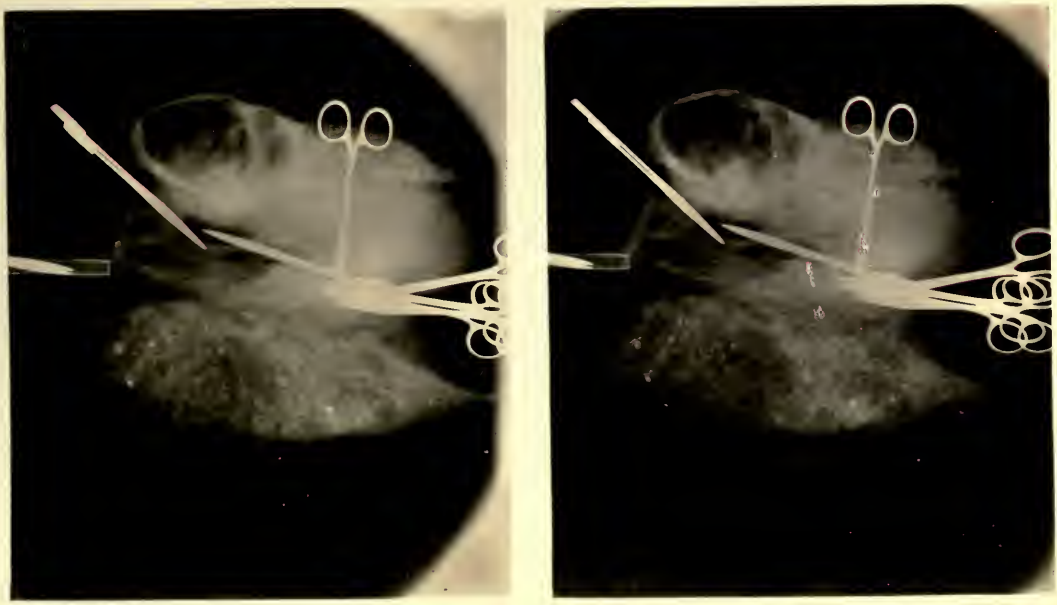

Class I.—Non-Tuberculous.

Normal Chest, with Fractured Clavicle.

[Stereo 6.]

¶ Aged twelve, perfectly healthy boy, with fracture of end of right clavicle. Note how horizontally first and second ribs are placed, as contrasted with those of older patients. Compare Stereo 34.

¶ Hilus shadows appear large, and two large calcified areas are seen at left, but these are usual in health and should not be made a basis for diagnosis of tuberculosis. Nowhere do the markings reach the periphery, except in the second interspace markings of the upper right, and these radiate and do not interweave.

¶ If this patient had clinical symptoms of tuberculosis, and ausculatory changes in the second interspace of right

Stereo 6. **Serial No. 1168**

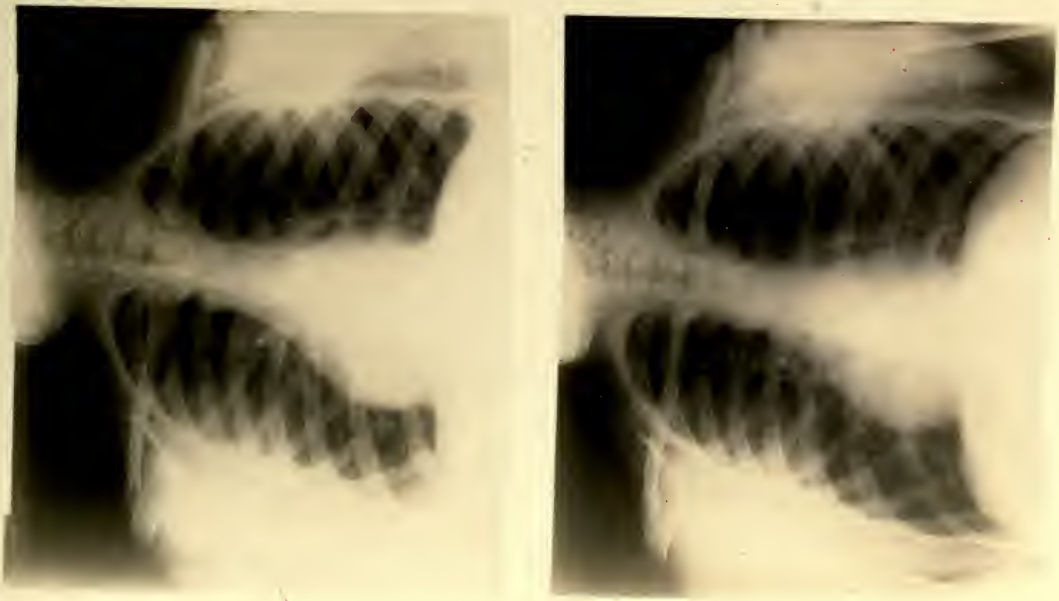

side, which even suggested tuberculosis, the case would have been classified as possibly tuberculosis, and kept under observation.

¶ Extra care should be used because this patient is only twelve, but if the patient were eighteen or over, no attention should be paid to such slight changes.

Marked Scoliosis.

[Stereo 7.]

¶ Patient is not suffering from tuberculosis. Age fifty-two. Spine curved sharply to the right, obscuring right thorax. Sternum seen from manubrium to ensiform. Heart appears as pear-shaped density, lying in the median line directly behind sternum. Trachea distorted to right, bifurcates in front of seventh rib. The right bronchus comes off in a straight line, while the left bronchus curves sharply to dip under the arch of the aorta.

¶ Coming off from the left bronchus, but somewhat distorted, are the vertebral, first interspace and second interspace trunks. In the left apex is seen a cloud of increased density extending up from the left of the trachea hugging the first rib. This is probably thickened pleura.

¶ History indicates that this deformity was caused by a fall from a horse when young.

¶ This stereo is reproduced because it allows us to study the mediastinum without interference of spine density.

Stereo 7. **Serial No. 1170**

Class II.—Tuberculous.

Tuberculous Mediastinitis.

[Stereo 8.]

¶ Cadaver—Autopsy proved the lung free from tuberculosis, but showed an extensive tuberculous mediastinitis.

¶ X-ray report—Hilus and trunk densities abnormally heavy, linear markings normal. Heavy density seen to the right of spine between the fifth and first ribs.

¶ X-ray diagnosis—Mediastinitis, probably tuberculous, with lung parenchyma practically normal.

¶ Thus it is easy in such a case to exclude pulmonary tuberculosis, but it is practically impossible to determine the etiology of such an extensive inflammation in the mediastinum. The lesions in the chest were not the cause of death.

Stereo 8. **Serial No. 1194**

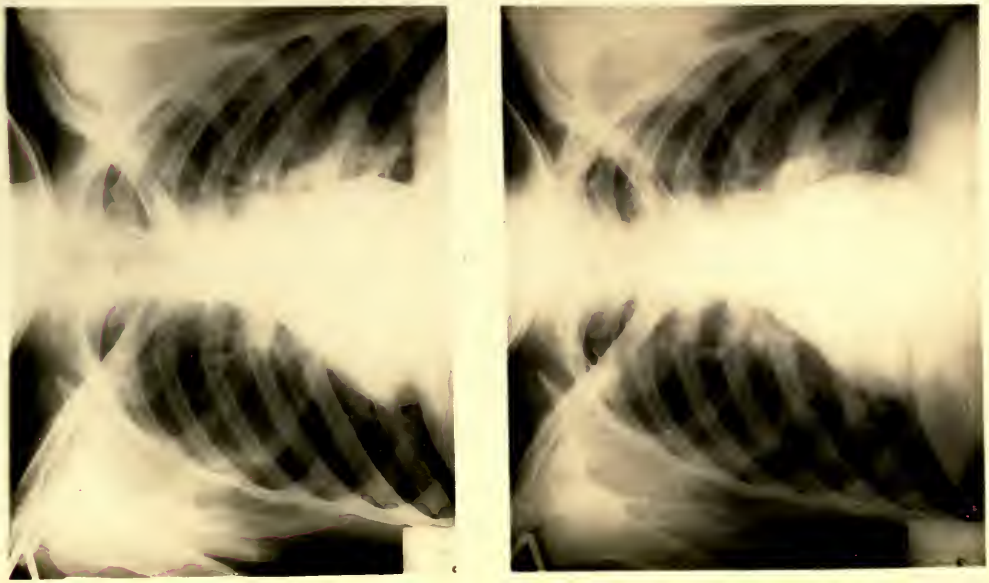

Early Tuberculosis.

[Stereo 9.]

¶ Tuberculosis in both upper lobes. Girl, aged twelve. Bones, diaphragm, heart and aortic densities normal. Hilus shadows large and studded by numerous calcified areas. Vertebral trunks at both apices heavy, and their linear markings, though faint, reach the periphery. Fine radiations, especially in the upper left lobe, are obscured by a faint cloud effect. Such a case in an adult would be classed as possibly tuberculosis and probably healed. But in a child such cases are usually active tuberculosis and require continued careful supervision. The mother was actively tuberculous.

¶ Physical examination—Right side to third rib impaired resonance, left front dull above clavicle. Posteriorly right suprascapular fascia dull. Left back normal, subcre-

Stereo 9. **Serial №** 1171

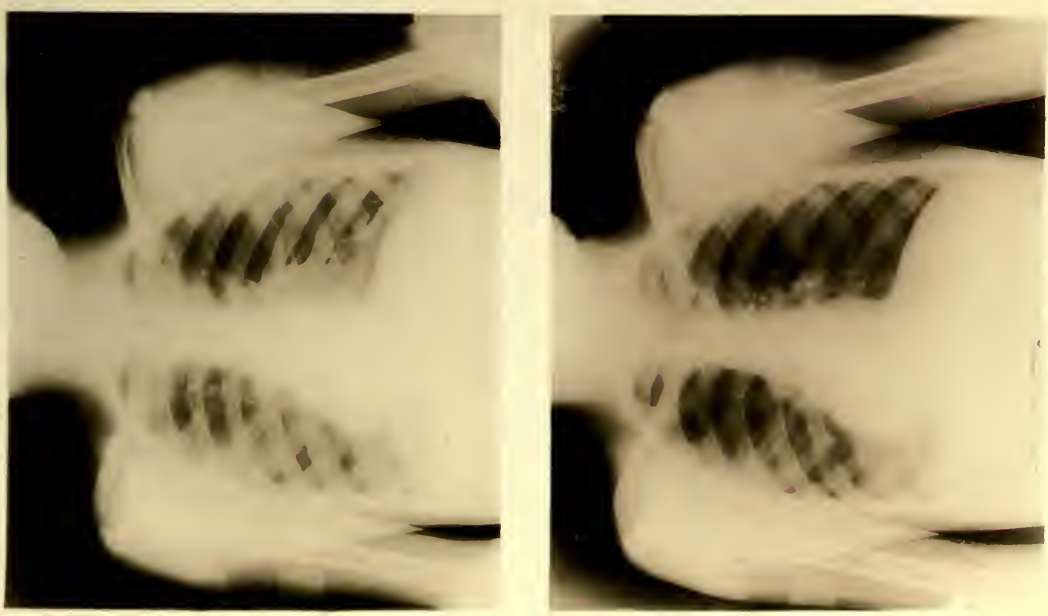

pitant rales on right side and back. Prolonged expiration over left front to third rib.

¶ Sputum negative from June, 1912, to October, 1913, when many bacilli were found for short time.

¶ Plate demonstrates clearly three trunks of upper, right division.

Active Pulmonary Tuberculosis.
[Stereo 10.]

¶ Female, pregnant. Diaphragms are pushed up and the heart slightly oblique.

¶ The hilus shadows have comparatively slight density. Behind the first interspace in both uppers is a faint filmy fan-shaped cloud which obscures the linear markings and extends from the periphery to the hilus. On the right side the lesion is largely limited to the first interspace trunks, but the second interspace trunks are involved. On the left side there is slight involvement of the vertebral and second interspace trunks. I believe the older lesion is on the left side.

¶ This case is characteristic of an active tuberculosis. Tubercle bacilli were found in the sputum and fine moist rales were heard on both sides below the clavicle. It should be noted that no calcified areas exist.

Stereo 10. **Serial No 1135**

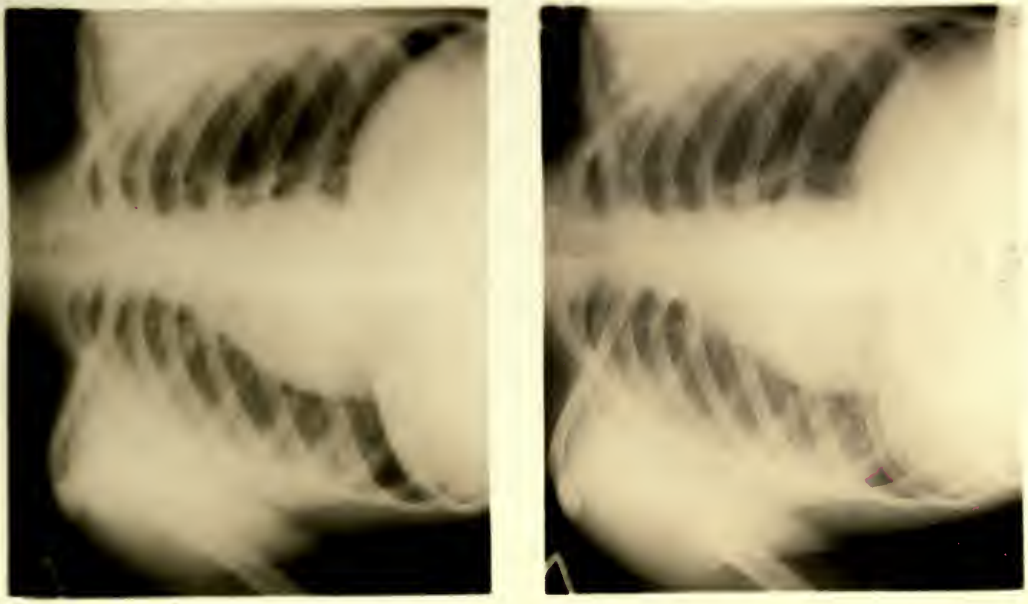

Early Tuberculosis.
[Stereo 11.]

¶ Male, twenty-nine, entered hospital in 1912, hemorrhage in 1910. Is living, well and working, May, 1914. Sputum positive, after repeated examinations.

¶ X-ray findings show lesion in the right upper and both bases. This plate is interesting, because the patient is apparently well, and because of unusual tuberculous lesions in the upper right.

¶ The right vertebral trunks are most involved, the lesion extending from the periphery to the very tip of the hilus.

¶ The right first interspace trunks are less involved, the markings not extending so nearly to the hilus, but met by the trunks fully half way. Their increased density is not so great. The second interspace trunk presents an interesting picture. Its density is intense, but less extensive than those of the other two, having a longer trunk from the cloud effect to the hilus.

Stereo 11. **Serial No. 1112**

Unilateral Tuberculosis.

[Stereo 12.]

¶ This is a stereo taken of a case which is more nearly unilateral tuberculosis than any other I have ever seen. Age forty-five. Diagnosed alcoholic bronchitis. Large moist rales over entire right side, both front and back from apex to base. Sputum negative on first examination. X-ray diagnosis at this time positively tuberculosis. Tubercle bacilli found in sputum only after repeated antiformin tests. Rib cartilages calcified.

¶ Trachea divides in front of sixth dorsal vertebra. Left thorax normal, except for bright calcified areas in hilus. Right thorax involved from apex to base, most definite lesion in right interspace trunks, which extends from periphery to hilus. Slight lesion in right vertebral trunk. First interspace trunk intermediately involved. Interlobular pleurisy seen behind third interspace. The anterior branch of the middle lobe trunks lies directly below this, between fourth rib and seventh interspace. Markings going to lower lobe show infection.

Stereo 12. **Serial No. 1194**

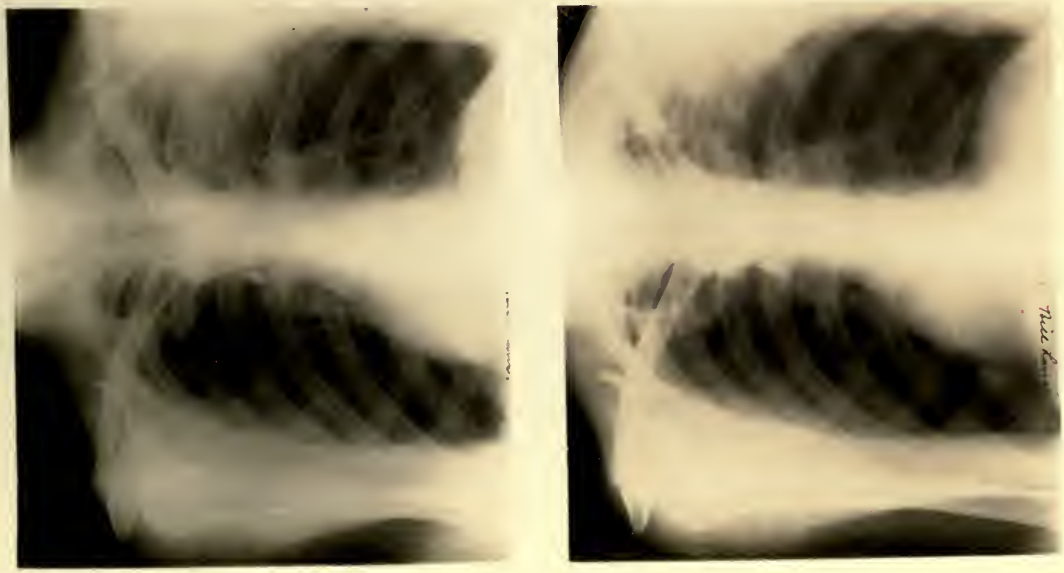

Pulmonary Tuberculosis. Active Effusion at Left Base.
[Stereo 13.]

¶ The usual tuberculous markings noted at upper left; an unusual density in second interspace trunk of upper right. Also slight amount of pleural effusion at left base. Aortic shadow wide and hilus shadows abnormally heavy. Pleural effusion shows characteristic density. The diaphragmatic curve replaced by effusion curve which extends from below upward and towards lateral wall.

¶ Tuberculous lesions extend from periphery to hilus shadows. On right, second interspace trunk groups are involved alone. Calcified area in right base in front of ninth interspace has no pathological significance. In upper left it is easily noted that heaviest density is in vertebral trunk and least density is that of second interspace group, whereas, first interspace trunks show intermediate change. All have the lesion extending from hilus to periphrey and I interpret the oldest infection of the upper left lobe in vertebral, next oldest in first, and last in second interspace trunks.

Stereo 13. **Serial No. 1194**

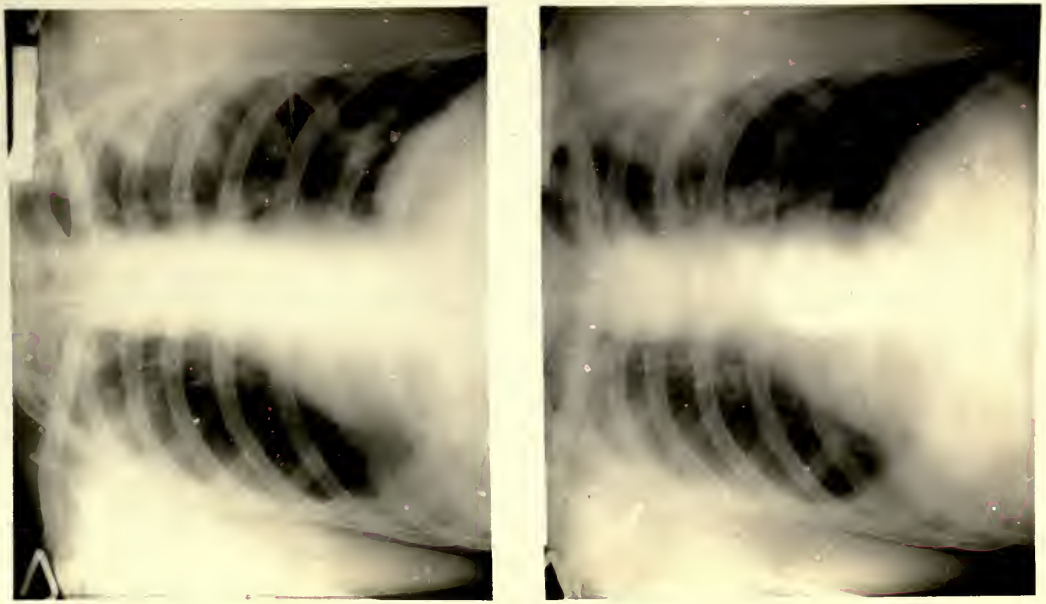

Pulmonary Tuberculosis, with Effusion.

[Stereo 14.]

¶ Pulmonary tuberculosis, extensive right base effusion. Ribs leave spine almost at right angles and interspaces wide. Heart and aorta pushed to left. Right diaphragm line replaced by effusion line. Characteristic tuberculous markings in both uppers.

¶ Upper right so much compressed that it is difficult to make out individual trunks, but it is easy to see studded, mottled cloud effect behind first rib, extending from periphery to hilus, and a lesion of distinctly less density, with more interweavings and finer studdings, extending from hilus to periphery behind first interspace.

¶ Left upper similar, except the heavier lesion is seen in first interspace group. Changes in markings of vertebral trunks seen within circle of first rib are almost as heavy, whereas, there is a very slight change of second interspace trunks to left side. Yet, in all these lesions, the disease extends from periphery to hilus.

Stereo 14. **Serial No. 1169**

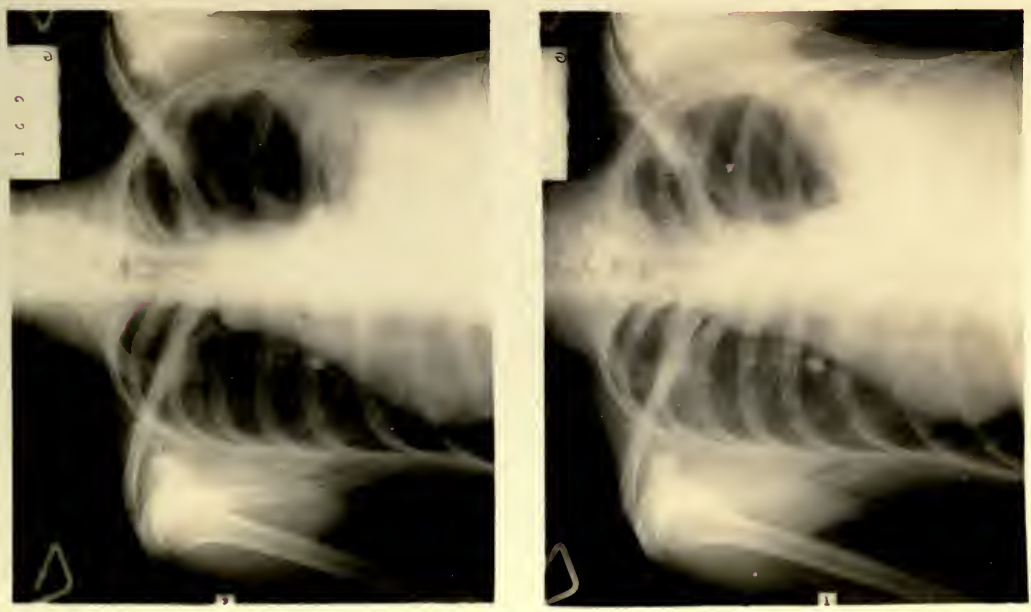

Pulmonary Tuberculosis. Interlobular Pleurisy on Right
[Stereo 15.]

¶ First rib cartilage not calcified. Pleura greatly thickened between upper and middle right lobes. Right first interspace trunks show tuberculous lesion. Linear markings obliterated by dense cloud effect which extends from hilus to periphery. Contrast this lesion with thickened pleura, and note that tuberculous lesion has its apex at hilus, while thickened pleura has its apex near periphery. Also note how much less involved are vertebral and second interspace trunks.

¶ Left upper most involved. Here most extensive and probably older lesion is in first interspace trunks. Vertebral trunk less involved. The lesions extend from hilus to periphery. Of second interspace trunks posterior branches most involved. These reach periphery of upper lobe, but not ribs, as lower lobe lies behind it.

¶ Such a lesion is pathognomonic of tuberculosis.

¶ Compare with Stereo 37.

Stereo 15. **Serial No. 1110**

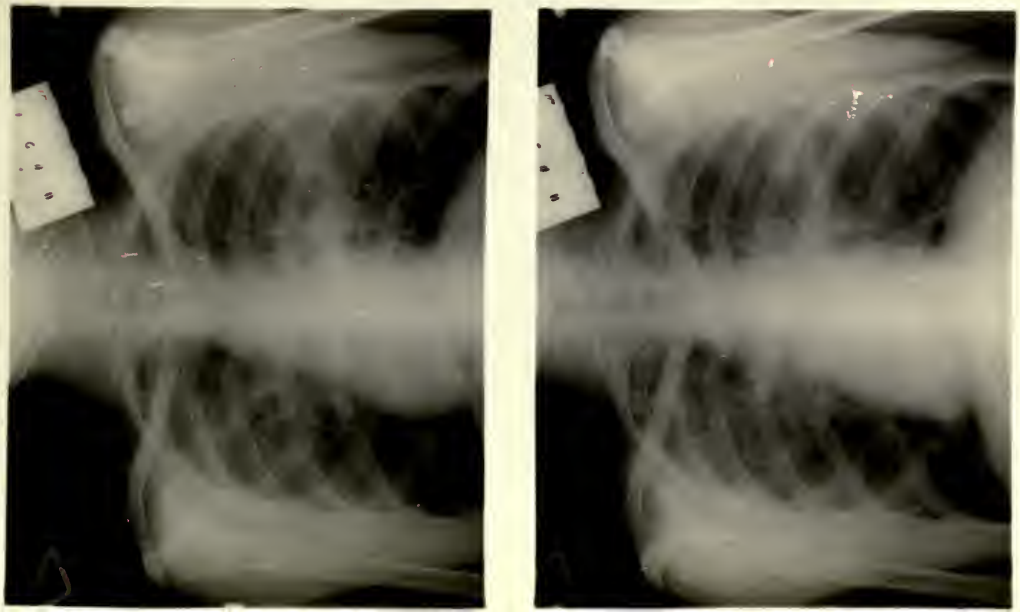

Pulmonary Tuberculosis, with Emphysema and Thickened Pleura.

[Stereo 16.]

¶ Thickened pleura at left base. Ribs leave spine at right angle, interspaces wide, diaphragm flat, heart separated from diaphragm. Hilus shadow heavy. Difficult to separate trunks in upper right, as all extend into a mottled cloud. Cloud very heavy within circle of first rib—behind first interspace mottled and reaches top of hilus, but behind second interspace cloud is fainter and trunk not so heavy.

¶ Such markings extending from hilus to periphery, and showing such a varying degree of change in the different trunk groups are pathognomonic of tuberculosis.

¶ Upper left divisions alone would be classified as possibly tuberculous. The contracture of eighth or ninth ribs to meet the trunks of the left base are characteristic of thickened pleura.

¶ The trunks of the lower right division are heavily studded, but the linear markings are not characteristically tuberculous. Compare Stereo 35.

Stereo 16. **Serial No. 1194**

Pulmonary Tuberculosis, with Abscess.
[Stereo 17.]

¶ Pulmonary tuberculosis, with tuberculous abscess in the posterior mediastinum. Note calcification of cartilages of the first, second, fifth and sixth ribs on right side and first on the left. Also the calcified areas in the right hilus and right base. The mediastinal abscess is seen posterior to and distinct from the heart density, and extends posterior to the diaphragm, mostly on the left side. The lung markings differ from those usually seen in tuberculous cases. The studdings are so numerous that to a large extent they obliterate the trunks as well as the linear markings, but careful study will show characteristic lesions in the vertebral, first interspace and second interspace trunks of the upper right. Thickened pleura is noted at the right apex.

¶ This form of tuberculosis is not so frequent as the fibroid form, neither is the prognosis so good.
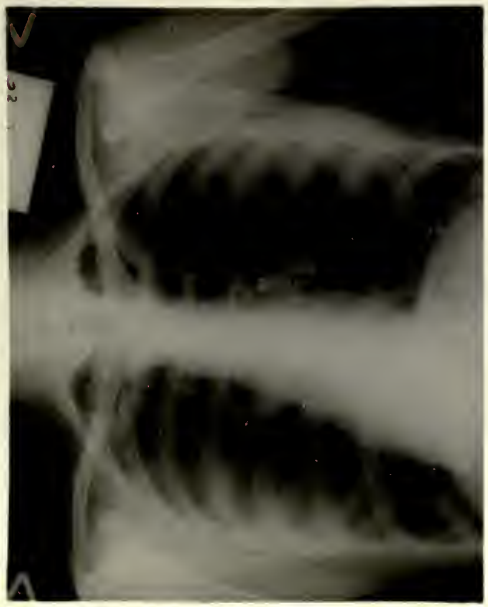
Stereo 17. **Serial No. 1117**